



8-20-2021

Large ureteric calculi and venous sinuses thrombosis of the brain led to behcet's dis-ease diagnosis in a child: a story to tell

Mosab Maree

Diana Dwaikat

Refat Hanbali

Ahmad Abu hassan

Taysir Alsadder

See next page for additional authors

Follow this and additional works at: <https://pmpj.najah.edu/journal>

Recommended Citation

Maree, Mosab; Dwaikat, Diana; Hanbali, Refat; Abu hassan, Ahmad; Alsadder, Taysir; Jaradat, Ahmad; Bahar, Sami; Aghbar, Amir; and Abushamma, Faris (2021) "Large ureteric calculi and venous sinuses thrombosis of the brain led to behcet's dis-ease diagnosis in a child: a story to tell," *Palestinian Medical and Pharmaceutical Journal*. Vol. 7: Iss. 2, Article 5.

Available at: <https://pmpj.najah.edu/journal/vol7/iss2/5>

This Research article is brought to you for free and open access by Palestinian Medical and Pharmaceutical Journal. It has been accepted for inclusion in Palestinian Medical and Pharmaceutical Journal by an authorized editor of Palestinian Medical and Pharmaceutical Journal. For more information, please contact mqneibi@najah.edu.

Large ureteric calculi and venous sinuses thrombosis of the brain led to behcet's dis-ease diagnosis in a child: a story to tell

Authors

Mosab Maree, Diana Dwaikat, Refat Hanbali, Ahmad Abu hassan, Taysir Alsadder, Ahmad Jaradat, Sami Bahar, Amir Aghbar, and Faris Abushamma

Large ureteric calculi and venous sinuses thrombosis of the brain led to behcet's disease diagnosis in a child: a story to tell

Mosab Maree^{1,2}; Diana Dwaikat^{1,3}; Refat Hanbali^{1,4}; Ahmad Abu hassan^{1,5};
Taysir Alsadder^{1,6}; Ahmad Jaradat^{1,7}; Sami Bahar^{1,3}; Amir Aghbar^{1,7} &
Faris Abushamma^{1,7}*

¹Department of Medicine, Faculty of medicine and health Sciences, An-Najah National University, Nablus, Palestine; ² Department of Radiology, An-Najah National University Hospital, Nablus, Palestine; ³ Department of Paediatrics, An-Najah National University Hospital, Nablus, Palestine; ⁴ Department of Rheumatology, An-Najah National University Hospital, Nablus, Palestine; ⁵ Department of Neurology, An-Najah National University Hospital, Nablus, Palestine; ⁶ Department of ENT, An-Najah National University Hospital, Nablus, Palestine; ⁷ Department of Urology, An-Najah National University Hospital, Nablus, Palestine

*Corresponding author: f.abushamma@najah.edu

Received: (1/2/2021), Accepted: (20/8/2021)

Abstract

Paediatric ureteric calculi are an uncommon conditions encountered occasionally by adult urologists. Endoscopic treatment is the mainstay treatment of such cases. Nevertheless, a significant percentage of children with ureteric calculi present with other comorbidities which is usually overlooked by urologists. In this article, we describe a rare case of paediatric ureteric calculi associated with deep venous sinuses thrombosis of the brain evaluated through a multidisciplinary approach that led to the final diagnosis of Behçet's disease which is also a rare condition in paediatrics. The complexity of the case in view of the rarity of both diseases encouraged us to report it. We present an eight-year-old male referred to a tertiary centre as a case of mastoiditis, complaining of severe headache, diplopia, and high-grade fever. Magnetic resonance venography "MRV" with intravenous "IV" contrast showed left transverse sigmoid and internal jugular dural venous sinus thrombosis but no evidence of mastoiditis. Computed tomography "CT" scan of the abdomen and pelvis showed a large left distal ureteric stones up to 4 cm collectively associated with hydronephrosis in addition to a few stones in the left kidney. He was managed by different teams such as urology, otorhinolaryngology, neurology, and ophthalmology to sort out his mysterious presentation over a lengthy hospital admission. Upon further evaluation and multi-disciplinary approach, a diagnosis of Behçet's disease has been made. Paediatric ureteric calculi are an uncommon problems and frequently presented with other comorbidities. Multi-disciplinary team approach to such cases is recommended and may uncover a serious underlying disease or concomitant comorbidities.

Keywords: Bachet's Disease; Brian Sinus Thrombus; Paediatric Stones; Diplopia.

INTRODUCTION

Paediatric ureteric calculi are uncommon but the incidence is constantly rising which leads to infrequent exposure

of such cases in many centres [1]. Age of the patients and the concomitant presence of other medical diseases are challenges facing the treating urologist in a paediatric cohort of patients [2]. However, as

urological surgeons, sometimes we overlook the patient's comorbidities and value the surgical procedure more. In this case, we highlight the importance of multi-disciplinary team "MDT" discussion of such cases as our patient had different complains which led eventually to the diagnosis of Behçet's disease, which is a rare diagnosis in the paediatric age group [3]. Furthermore, we think that the association between acute ureteric calculi, brain dural sinus thrombosis, and Behçet's disease is worth telling such a story.

Case presentation

An eight-years-old male presented to the paediatric outpatient with a history of headache for 17 days associated with vomiting and left ear pain. The headache was worse by the end of the day and associated with left eye diplopia and frequent spikes of high-grade fever which

was treated by general practitioners "GPs" with different types of antibiotics but with no improvement, so he was referred as a case of left sided mastoiditis.

He was admitted to our tertiary hospital where urgent ophthalmology and neurology evaluation were arranged. Upon ophthalmology evaluation, left-sided papilledema grade 4 and right-sided papilledema grade 3 were discovered. Furthermore, Magnetic resonance venography "MRV" with intravenous "IV" contrast was done and reported by our radiologist to have left transverse sigmoid and internal jugular dural venous sinuses thrombosis but no space occupying the lesion (Figure 1). Otorhinolaryngology assessment showed no signs of mastoiditis and temporal bone computed tomography "CT" showed no evidence of mastoiditis.

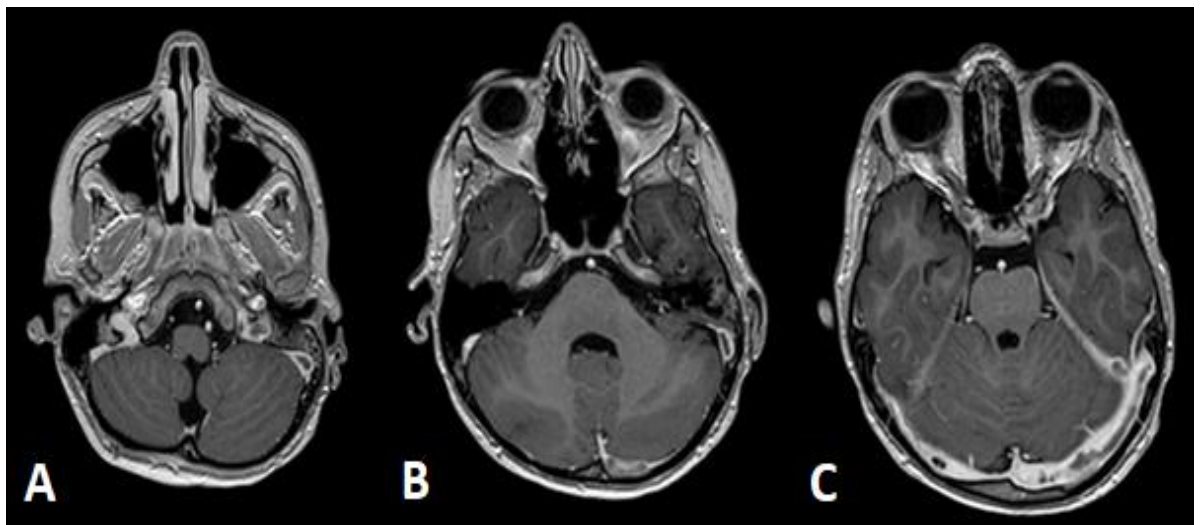


Figure (1): T1WI post-contrast administration / MRV with IV contrast shows left internal jugular (A), sigmoid (B), and transverse (C) dural venous sinuses filling defects (dural venous sinus thrombosis).

Lab test showed normal Antithrombin III levels, negative perinuclear anti-neutrophil cytoplasmic antibodies "P-ANCA", and cytoplasmic anti-neutrophil cytoplasmic antibodies "C-ANCA", but

thrombophilia profile showed factor V laden heterozygosity. Diagnostic and therapeutic lumbar puncture was done so meningitis was excluded and intracranial pressure calmed down which was reflect-

ed on significant improvement of his headache.

A regime of Enoxaparin (1 mg/ kg/ dose), twice daily, Acetazolamide (10 mg/ kg/ day), and ceftriaxone to cover brain sinus thrombosis, high intracranial pressure and possible mastoiditis had been initiated. However, a few days later, headache increased and repeated ophthalmological exam showed minimal improvement in papilledema, diplopia, and relative afferent pupillary defect (RAPD) was still present along with bilateral 6th cranial nerve paresis. Therefore, Acetazolamide dose was increased to 25mg/kg/day which improved his headache and his papilledema.

Few days later, he suddenly developed sudden onset severe left flank pain with gross haematuria and significant rise of his serum creatinine. Ultrasound scan followed by CT without contrast showed

the presence of a large left distal ureteric stones up to 4 cm collectively associated with left hydronephrosis in addition to a few stones in the left kidney (Figure 2).

Final diagnosis and treatment

An urgent urology evaluation was sought. Urgent 18 cm (4F) ureteric stent was inserted under spinal anaesthesia performed by a paediatric anaesthetist. His symptoms improved dramatically alongside with significant improvement of his serum creatinine. He had no family history of stones and no previous attacks or ureteric colic.

Until now, the case is managed by different teams but with no obvious diagnosis to explain the progressive deterioration of his clinical status. Thus, the case was discussed in the main hospital meeting which is arranged on a weekly basis to discuss such unusual cases.

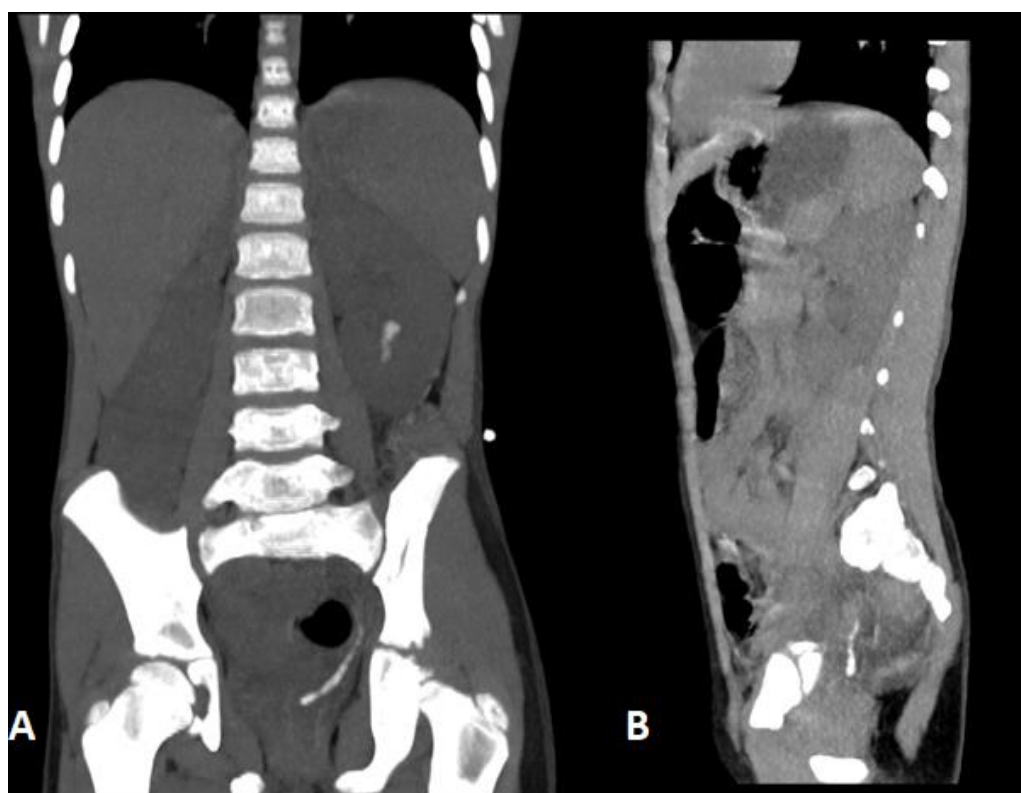


Figure (2): CT scan without contrast (Coronal (A) and sagittal (B) views): 4 cm left distal ureteric stones and small left kidney stones.

A rheumatologist suggested Paediatric Bachet disease as a potential diagnosis and it came out as a shock to all attendees and specialities. Detailed history was taken from his mother who mentioned history of recurrent ulcers and a positive family history of Bachet disease. He met the clinical criteria of pediatric Bachet disease; as he had recurrent oral aphthosis with more than 3 attacks per year, skin involvement manifested by pseudofolliculitis and erythema nodosum, neurological signs as he had papilledema, diplopia and relative afferent papillary defect (RAPD) along with bilateral 6th cranial nerve Paresis. Furthermore, he also had vascular signs manifested by venous sinus thrombosis. Thus, four out of six items were found which confirmed the clinical diagnosis of pediatric Bachet disease[4]. Therefore, Azathioprine, Colchicine, and steroids were initiated. Prior to discharge, ophthalmological exam

showed dramatical improvement in all features mentioned before.

Six weeks later, the patient had ureteroscopy and laser lithotripsy with complete clearance of his stones and removal of his stent. Stones were soft, easily dusted, and performed as a day case procedure as encouraged by current guidelines during coronavirus disease of 2019 "COVID-19" pandemic[5].

Outcome

Three months later, he visited our outpatient clinic and he was seen by urology, neurology, rheumatology, and paediatrics. His clinical status was excellent and he was compliant with his medications. Brain magnetic resonance imaging "MRI" scan showed complete resolution of his brain sinuses thrombosis, Figure 3. Furthermore, detailed urinary tract ultrasound showed no residual stone fragments or new stones.

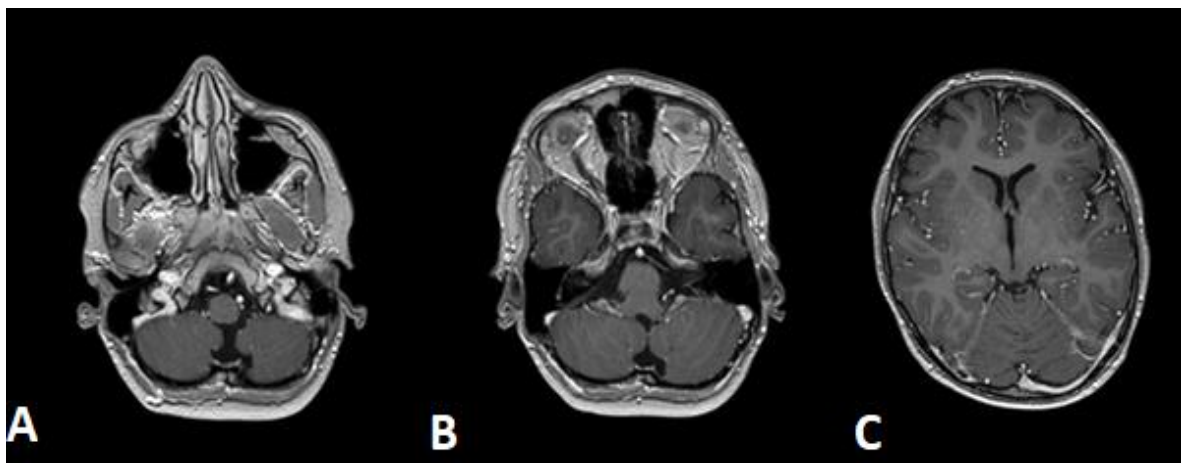


Figure (3): Resolution of sinuses thrombus upon follow up MRI scan in the left internal jugular (A), sigmoid (B), and transverse (C) dural venous sinuses.

DISCUSSION

Paediatric ureteroscopy and acute ureteric calculi are an infrequently encountered problems which needs special attention in view of patient's age, the presence of comorbidities and the future

risk of developing further stones [1]. Therefore, a thorough evaluation and comprehensive work-up should be considered to unmask any potential underlying cause to initiate proper treatment and prevent future stone formation [2].

Behcet's disease is also a rare condition to be diagnosed in the paediatric age group [3]. Clinical criteria to diagnose paediatric Behcet's disease should be met prior to treatment initiation, which was evident in our patient [4, 6]. Central nervous system involvement as the main feature of paediatric Behçet disease not only obscured the diagnosis but also made any intervention risky and potentially associated with adverse outcome [7]. For instance, our patient required spinal anaesthesia to deal with his stones as well as to decrease intra-cranial pressure during the procedure.

The merit of this story is that such patients are usually exposed to different specialities such as paediatrics, paediatric nephrology, neurology, urology, radiology, paediatric anaesthesia and finally rheumatology as in our case. Thus, we strongly recommend that all paediatric stones to be evaluated and managed as part of a special MDT in order not to miss a serious diagnosis and to prevent future risk of stone formation. Future research should focus on possible relation of Behcet's disease with ureteric stone and help establish prophylactic strategies.

CONCLUSION

Paediatric ureteric stones are uncommon and can be managed safely by urologists. However, MDT approach is recommended to optimize the outcome.

ETHICAL CONSIDERATION

Informed written consent was signed by the patient's parents, and they were informed that all the patient personal data will be disclosed from the public.

ACKNOWLEDGEMENTS

The authors would like to thank the Clinical Research Center of An-Najah National University Hospital for their wise pieces of advice.

AUTHOR DISCLOSURE STATEMENT

The authors declare that they have no competing interests.

REFERENCES

- 1) Jobs K, Rakowska M, Paturej A. Urolithiasis in the pediatric population - current opinion on epidemiology, pathophysiology, diagnostic evaluation and treatment. *Dev Period Med.* 2018; 22(2): 201-208.
- 2) Issler N, Dufek S, Kleta R, Bockenhauer D, Smeulders N, Van't Hoff W. Epidemiology of paediatric renal stone disease: a 22-year single centre experience in the UK. *BMC Nephrol.* 2017; 18(1): 136.
- 3) Eldem B, Onur C, Ozen S. Clinical features of pediatric Behçet's disease. *J Pediatr Ophthalmol Strabismus.* 1998; 35(3):159-161.
- 4) Kone-Paut I. Behcet's disease in children, an overview. *Pediatr Rheumatol Online J.* 2016; 14(1): 10.
- 5) Abushamma F, Jaradat A, Al-azab R, Demour SA, Albuheissi S, Mustafa A, et al. Recommendations and algorithm to deal with urological surgeries in the Middle East during COVID-19 Pandemic: Review article and regional expert opinion. *Pal Med Pharm J.* 2020; 5(2): 133-139.
- 6) Yildiz M, Haslak F, Adrovic A, Sahin S, Koker O, Barut K, et al.

- Pediatric Behcet's Disease. *Front Med (Lausanne)*. 2021; 8: 627192.
- 7) Costagliola G, Cappelli S, Consolini R. Behcet's Disease in Children: Diagnostic and Management Challenges. *Ther Clin Risk Manag*. 2020;16: 495-507.