



9-18-2021

## Syringomyelia unusually presented with isolated lower urinary tract dysfunction: a case report

Ahmad Jaradat

Jawad Ziyadeh

Faris Abushamma

Azza Ziyadeh-Isleem

Follow this and additional works at: <https://pmpj.najah.edu/journal>

---

### Recommended Citation

Jaradat, Ahmad; Ziyadeh, Jawad; Abushamma, Faris; and Ziyadeh-Isleem, Azza (2021) "Syringomyelia unusually presented with isolated lower urinary tract dysfunction: a case report," *Palestinian Medical and Pharmaceutical Journal*: Vol. 7: Iss. 2, Article 6.

Available at: <https://pmpj.najah.edu/journal/vol7/iss2/6>

This Research article is brought to you for free and open access by Palestinian Medical and Pharmaceutical Journal. It has been accepted for inclusion in Palestinian Medical and Pharmaceutical Journal by an authorized editor of Palestinian Medical and Pharmaceutical Journal. For more information, please contact [mqneibi@najah.edu](mailto:mqneibi@najah.edu).

## Syringomyelia unusually presented with isolated lower urinary tract dysfunction: a case report

Ahmad Jaradat<sup>1\*</sup>; Jawad Ziyadeh<sup>2</sup>; Faris Abushamma<sup>1</sup> & Azza Ziyadeh-Isleem<sup>3</sup>

<sup>1</sup> Department of Urology, An-Najah National University Hospital, An-Najah National University, Nablus, Palestine. <sup>2</sup> Department of Neurosurgery, An-Najah National University Hospital, An-Najah National University, Nablus, Palestine. <sup>3</sup> Department of Biomedical Sciences, An-Najah National University, Nablus, Palestine.

\*Corresponding author: a.jaradat@najah.edu

Received: (3/2/2021), Accepted: (18/9/2021)

### Abstract

We report the case of a 9-year-old girl who presented to our hospital at the age of 6 years with recurrent febrile urinary tract infections started at 6 months, associated with nocturnal enuresis, daytime urinary frequency, and urge incontinence. Initial evaluation revealed a routine physical exam with no evidence of neurological abnormalities. Urinary tract ultrasound failed to demonstrate structural abnormalities; micturition cystourethrogram documented the absence of vesicoureteral reflux. Accordingly, the urodynamic study demonstrated the presence of low bladder compliance and reduced bladder capacity. A whole spine magnetic resonance imaging showed isolated syringomyelia extending from T4 to T12 and measuring about 2.7mm in anterior-posterior (AP) diameter at the D8D9 level. After the failure of initial management of bladder overactivity using anticholinergic medications, the patient was managed by repeated cystoscopic injections of 200 international units of OnabotulinumtoxinA, with good symptomatic relief. After three years of follow-up 3 years, investigations and clinical findings failed to demonstrate neurological or urodynamic deterioration.

**Keywords:** Neurogenic Bladder, Syringohydromyelia, Overactive Bladder, Pediatric, Spinal Dysraphism.

### INTRODUCTION

Neurogenic bladder in children remains frequently presented to pediatric, urologic, and neurosurgical outpatient clinics. The most common cause of pediatric neurogenic bladder is open or closed spinal dysraphism. Lipomyelomeningocele, tethered spinal cord, and split-cord syndrome is the most common examples (1). The usual presentation of spinal dysraphism comprises specific skin stigmata as in closed spina bifida, sensorimotor deficits of lower limbs with associated orthopedic deformities, and urinary symptoms. Children may also complain of back and lower limb pain at an older age. A neurogenic bladder with a neural dysfunction of the urinary bladder can present with lower urinary tract symptoms, urinary incontinence, nocturnal enuresis, recurrent infections, or vesicoureteral reflux (2). Conservative management of patients with neurogenic bladder aims to preserve kidney function and decrease recurrent infections and incontinence

episodes. Anticholinergics, Botulinum toxin injection, with or without clean intermittent catheterization (3), and sometimes interventions to correct vesicoureteral reflux and bladder augmentation can be used. In addition, neurosurgical interventions may be needed to correct the specific neural axis anomaly, mainly the spinal dysraphism (4).

It is not uncommon for a spina bifida occulta to present only with urinary symptoms, but it is rare for syringomyelia-fluid-filled cavitation of the spinal cord- to do so. This article presents a case of idiopathic syringomyelia presenting with a neurogenic bladder without other neurological or orthopedic manifestations.

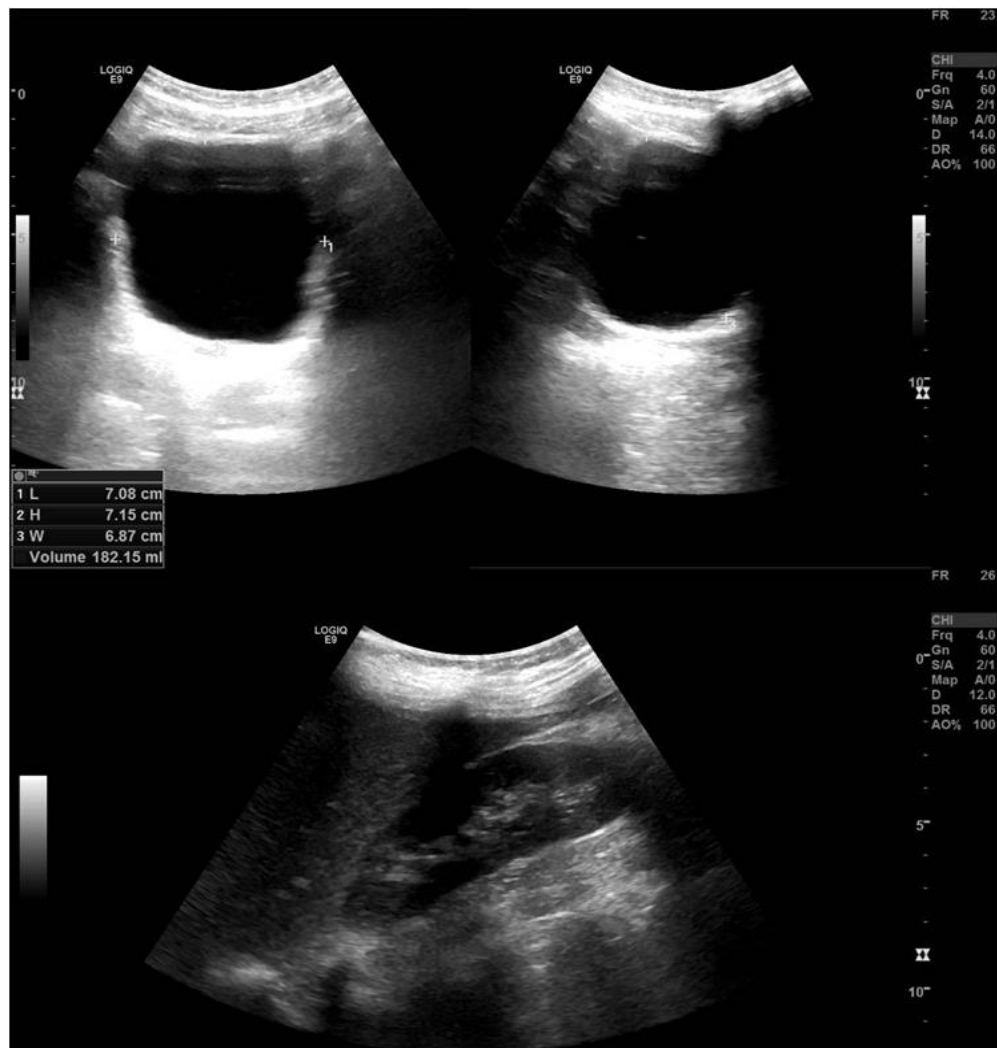### RESULTS

#### Case report

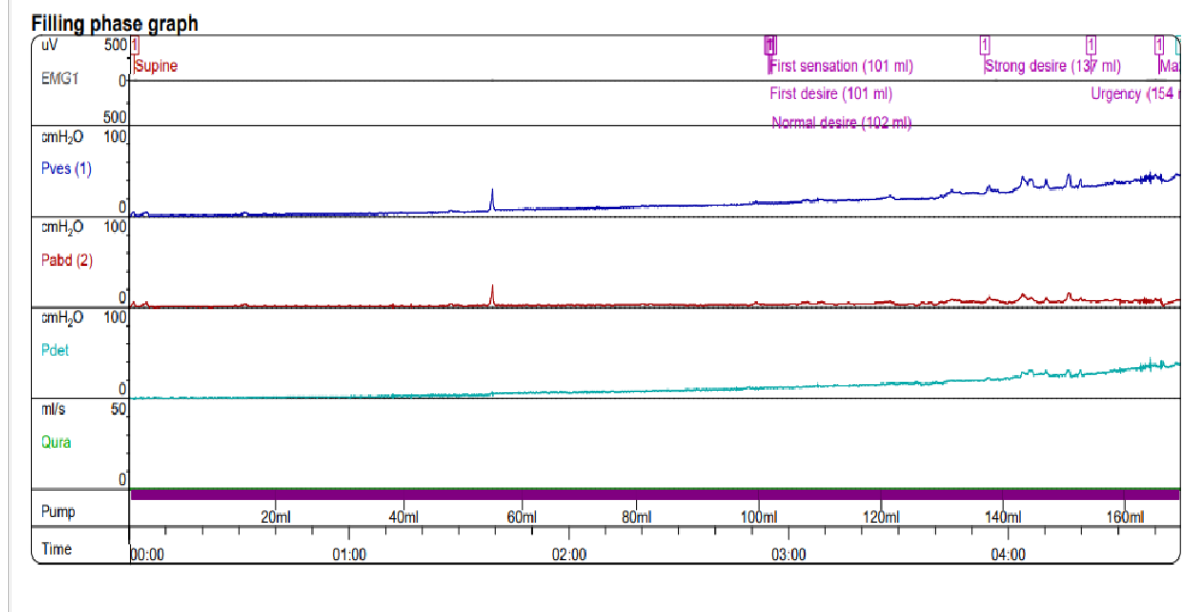
A 9-year-old girl, a product of normal vaginal delivery at full term. Presented to our hospital at the age of 6 years with recurrent urinary tract infections (UTI) started at 6 months, associated with nocturnal enuresis

and daytime urinary frequency and urge incontinence. Micturition cystourethrogram (MCUG) was done and showed no evidence of vesicoureteral reflux; a urinary tract ultrasound scan showed no abnormalities (Figure 1). After treating UTI, a urodynamic study was done at a filling rate of 20ml/min. It showed evidence of detrusor overactivity associated with low bladder compliance as detrusor pressure reached up to 60 cmH<sub>2</sub>O at an instilled volume of 160 ml (Figure 2). Complete bladder emptying was documented, with normal voiding curve and regular sphincteric activity during the voiding phase. The neurological evaluation showed a typically developed girl not complaining of back or lower limb pain or sensorimotor deficit with normal deep tendon reflexes and gait—no skin stigmata of spinal dysraphism.

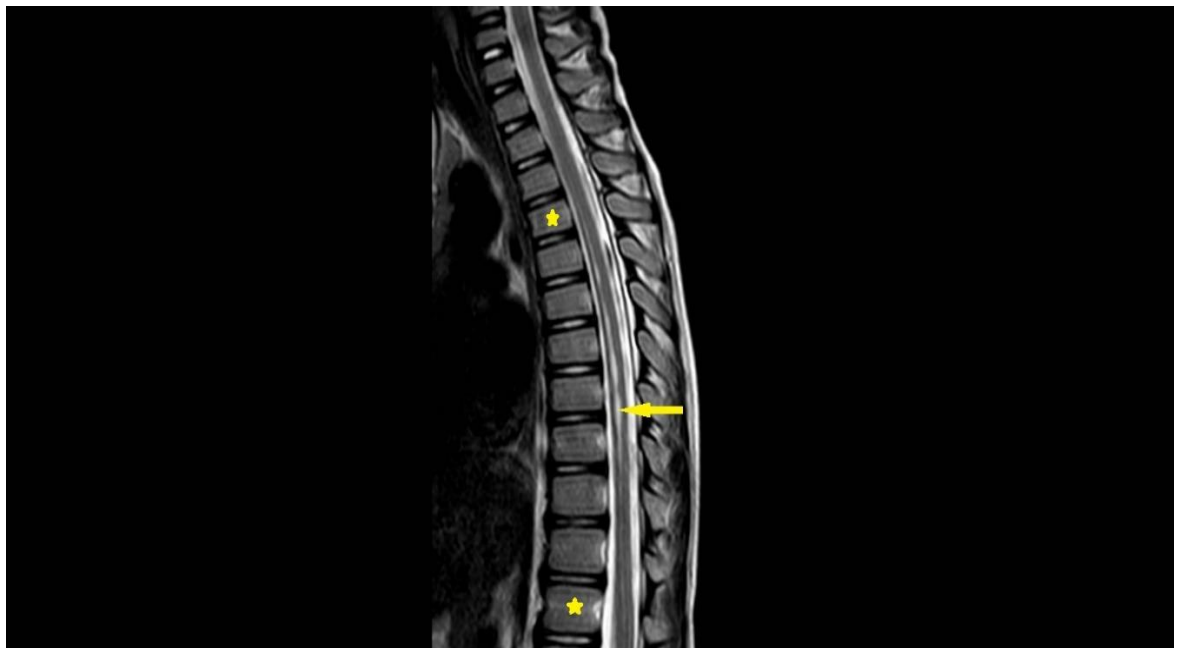A whole-spine MRI revealed a regular lying cord ending at the L1 vertebral body level with no kyphoscoliosis, tethered cord, split cord syndrome, or spinal dysraphism, as well as syringomyelia extending from T4 to T12 and measuring maximally about 2.7mm in anterior-posterior (AP) diameter at the D8D9 level (Figure 3). An MRI of the brain revealed no Chiari malformation or other abnormalities (Figure 4). The patient was started on the maximum dose of oxybutynin without significant improvement. As medical treatment failed, endoscopic injection of 200 international units of OnabotulinumtoxinA was tried with excellent symptomatic relief. During 3 years of follow-up, the Onabotulinumtoxin A injection was repeated twice. Urodynamic testing and radiological follow-up at one and 3 years showed no significant deterioration (Figure 5) (Figure 6).



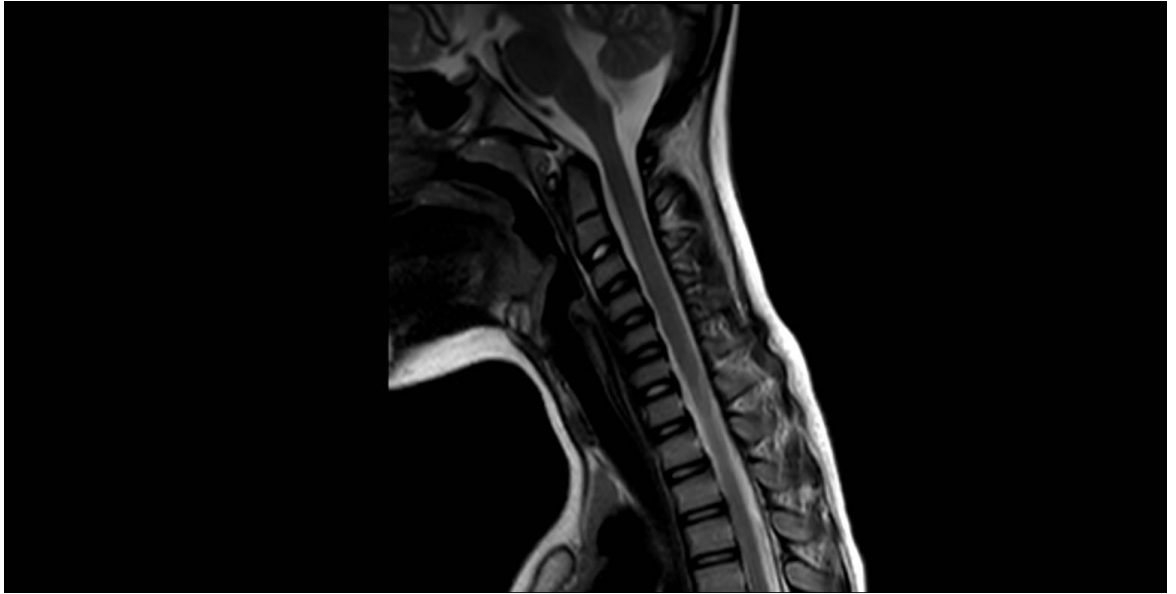
**Figure (1):** Urinary tract ultrasound showing normal kidneys and urinary bladder at the initial presentation.



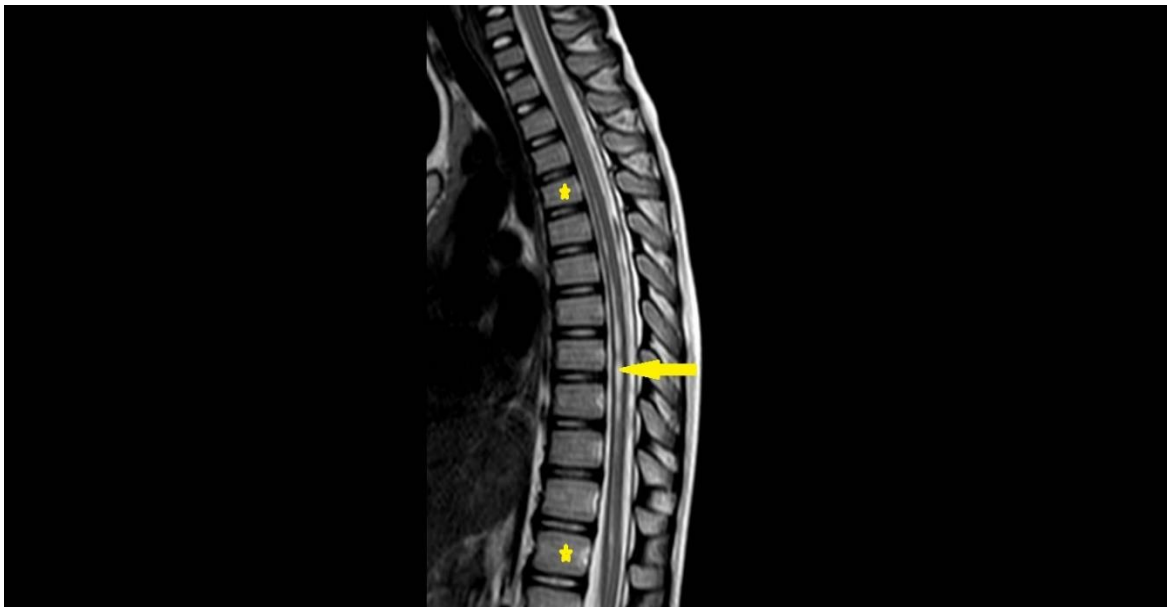**Figure (2):** Urodynamic study showing low bladder compliance (60cm H<sub>2</sub>O) and reduced capacity (160 ml).



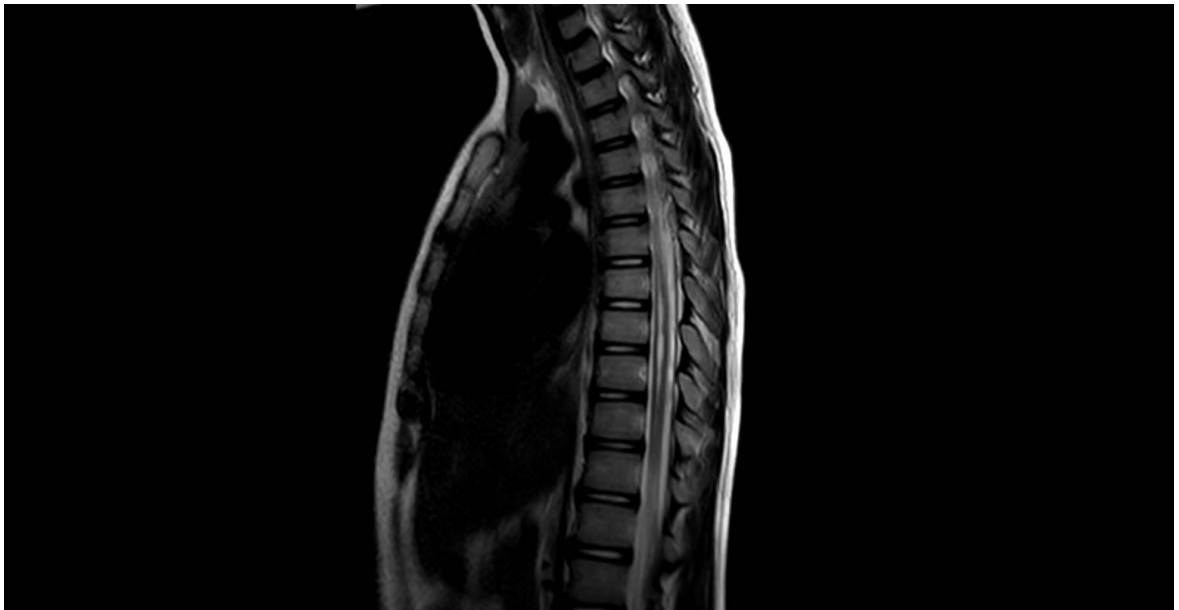**Figure (3):** First MRI spine, sagittal T2 sequence showing syringomyelia of 2.7 mm in AP diameter (yellow arrow) extending from T4 to T12 (stars).



**Figure (4):** Sagittal T2 MRI sequence of craniocervical junction showing no Chiari malformation or other junctional anomalies.



**Figure (5):** Sagittal T2 MRI sequence at 1 year of follow-up showing a mild increase in the transverse diameter of the syringomyelia (yellow arrow) extending from T4 to T12 (stars).



**Figure (6):** Sagittal T2 MRI sequence at 3 years of follow-up showing mild regression of syringomyelia.

## DISCUSSION

Among children presenting with symptoms of neurogenic bladder, a spectrum of neurological anomalies of the neuraxis can be revealed, primarily spinal dysraphism. However, our patient's history and physical examination were not suggestive of any neurological deficit or orthopedic anomaly of the spine and lower limbs, and she had no previous history of falling spinal trauma or meningitis. Her magnetic resonance imaging of the craniospinal axis did not show any spinal dysraphism at the origin of this neurogenic bladder. Specifically, no radiologic evidence of lipomyelomeningocele, tethered cord, diastematomyelia, and Chiari malformation, but it showed syringomyelia in the dorsal spinal cord extending from the T4 vertebral body down the terminal cone at T12. It initially measured about 2.5mm at the diagnosis at the age of 6 years and slightly increased to 3mm within the following three years of follow-up. Our patient was diagnosed with idiopathic primary syringomyelia, which is thought to develop due to cerebrospinal fluid flow abnormalities(4). By reviewing the literature, idiopathic syringomyelia in children was shown to have a benign course that is best managed expectantly and conservatively in most cases (5, 6), as it usually remains stable over time (7).

Given that our patient did not show any clinical or radiological deterioration, neurosurgical interventions, such as syrinx fenestration and syringe-subarachnoid or syringe-peritoneal shunting(4), were not considered as part of her management plan. In addition, such patients need close urologic follow-up with different medical and surgical interventions to protect kidney function and control urinary incontinence episodes and recurrent infections. In our patient, we managed her conservatively by repeated OnabotulinumtoxinA injection as there is no clear indication for more invasive surgical interventions (8).

## CONCLUSION

Although rare, primary idiopathic syringomyelia can be the origin of the isolated neurogenic bladder among children. Proper neurological evaluation and neuroimaging for children with lower urinary tract dysfunction are helpful, even without noticeable neurological abnormalities.

## REFERENCES

- 1) Nejat F, Radmanesh F, Ansari S, Tajik P, Kajbafzadeh A, El Khashab M. Spina bifida occulta: is it a predictor of underlying spinal cord abnormality in patients with lower urinary tract dysfunction? *Journal of neurosurgery Pediatrics*. 2008; 1(2): 114-7.

- 2) Thomas L, Harding C. Urodynamics in the Neurological Patient. In: Dolan L, Toozs-Hobson P, Thakar R, editors. *Manual of Urodynamics for Gynaecologists*. Cambridge: Cambridge University Press; 2020. p. 85-91.
- 3) Geljic A, Abdovic S, Stampalija F, Loncar L, Tripalo BA, Cuk M. An Unusual Case of Syringohydromyelia Presenting with Neurogenic Bladder. *European journal of pediatric surgery reports*. 2019; 7(1): e79-e82.
- 4) Roy AK, Slimack NP, Ganju A. Idiopathic syringomyelia: retrospective case series, comprehensive review, and update on management. *Neurosurgical focus*. 2011; 31(6): E15.
- 5) Joseph RN, Batty R, Raghavan A, Sinha S, Griffiths PD, Connolly DJ. Management of isolated syringomyelia in the paediatric population--a review of imaging and follow-up in a single centre. *British journal of neurosurgery*. 2013; 27(5): 683-6.
- 6) Magge SN, Smyth MD, Governale LS, Goumnerova L, Madsen J, Munro B, et al. Idiopathic syrinx in the pediatric population: a combined center experience. *Journal of neurosurgery Pediatrics*. 2011; 7(1): 30-6.
- 7) Singhal A, Bowen-Roberts T, Steinbok P, Cochrane D, Byrne AT, Kerr JM. Natural history of untreated syringomyelia in pediatric patients. *Neurosurgical focus*. 2011; 31(6): E13.
- 8) Kavanagh A, Baverstock R, Campeau L, Carlson K, Cox A, Hickling D, et al. Canadian Urological Association guideline: Diagnosis, management, and surveillance of neurogenic lower urinary tract dysfunction - Full text. *Canadian Urological Association journal = Journal de l'Association des urologues du Canada*. 2019; 13(6): E157-e76.